



Research article

Seasonal variation of parasitic infections in Asian swamp eels (*Monopterus albus*) from local markets in Yangon, Myanmar

Aung Phyto Wai^{1,2,3}, Panupan Sripan^{2,3,4}, Thidarut Boonmars^{1,2,3,*}, Pranee Sriraj^{2,3,5}, Ratchadawan Aukkanimart^{2,3,5}, Jiraporn Songsri^{2,3,4}, Parichart Boueroy^{2,3,6}, Sirintip Boonjaraspinyo⁷, Sukhonthip Khueangchaingkhwang^{1,2,3}, Porntip Laummaunwai¹, Zhiliang Wu⁸, Benjamabhorn Pumhirunroj^{1,2,3,9}, Atchara Artchayasawat^{1,2,3}, Kanpicha Chomphumee², Panaratana Rattanasuwan¹⁰, Chatanun Eamudomkarn^{1,2}, Opal Pitaksakulrat¹ and Nuttapon Ekobol¹

¹Department of Parasitology, Faculty of Medicine, Khon Kaen University, Khon Kaen 40002, Thailand

²Cholangiocarcinoma Research Institute, Khon Kaen University, Khon Kaen 40002, Thailand

³Neglected, zoonosis and vector-borne disease research group, Khon Kaen University, Khon Kaen 40002, Thailand

⁴College of Allied Health Science, Suan Sunandha Rajabhat University, Samut Songkhram 75000, Thailand

⁵Department of Traditional Medicine, Faculty of Natural Resources, Rajamangala University of Technology ISAN Sakon Nakhon Campus, Sakon Nakhon 47160, Thailand

⁶Faculty of Public Health, Kasetsart University Chalermphrakiat Sakon Nakhon Province Campus, Sakon Nakhon 47000, Thailand

⁷Department of Community Medicine, Faculty of Medicine, KhonKaen University, KhonKaen 40002, Thailand

⁸Department of Parasitology, Faculty of Medicine, Gifu University, Gifu, Japan

⁹Program in Animal Science, Faculty of Agriculture Technology, Sakon Nakhon Rajabhat University, Sakon Nakhon 47000, Thailand

¹⁰Department of Anesthesiology, Faculty of Medicine, Khon Kaen University, Khon Kaen 40002, Thailand

Abstract

Several parasites from eels are the zoonosis and clinically important, as they can cause food-borne parasitic zoonoses in humans. In this study, parasitic infections in Asian swamp eels (*Monopterus albus*) were observed from local market in Yangon, Myanmar in rainy, cold and hot seasons during 2016-2017. Asian swamp eels were purchased from local market in Yangon, Myanmar and observed parasitic infection using liver and intestine dissection, staining and identification under microscopy. The data were analyzed using Pearson's chi-squared test and Bonferroni correction. Asian swamp eels were infected with several parasites, such as *Gnathostoma*, Acanthocephalan, *Clinostomum complanatum* and *Bothriocephalus Rudolphi*, 1808. The most of parasites were *Gnathostoma* subsequent to Acanthocephalan. The highest number of *Gnathostoma* larvae was found in rainy season, and the highest number in a single eel was 69 and 4.8 larvae per eel. The highest number of Acanthocephalan was found in cold season, 117 adults and 1.8 adult per eel. *Gnathostoma* larvae were observed in both the intestines and livers. Acanthocephalan adults were observed in only the intestines. This is the first report that has found Acanthocephalan, *B. claviceps* and *C. complanatum* in Asian swamp eels from Myanmar. This study suggests that concerning of eating uncooked eel or processing eel is very importance, which may cause of human parasitic infection.

Keywords: Acanthocephalan, Asian swamp eels, *Gnathostoma*, Myanmar

*Corresponding author: Thidarut Boonmars, Department of Parasitology, Faculty of Medicine, Khon Kaen University, Khon Kaen 40002 Thailand. Tel: +66 43 348387; fax: +66 43 202475, Email: bthida@kku.ac.th ; boonmars@yahoo.com

Article history: received manuscript: 25 February 2019,
 revised manuscript: 26 March 2019,
 accepted manuscript: 23 April 2019,
 published online: 8 July 2019

Academic editor: Korakot Nganvongpanit

INTRODUCTION

Asian swamp eels (*Monopterus albus*) are used for special dishes in Asian countries, have been reported for the host of several parasitic such as *Gnathostoma*, acanthocephalans, trematodes, cestodes, trypanosome species, metacercariae of digenea, and others nematode species (Chai et al., 2015; Herman and Chiodini, 2009; Sieu et al., 2009; Sugaroon and Wiwanitkit, 2003). Several species of the genus *Gnathostoma* are clinically important, as they can cause food-borne parasitic zoonoses in humans. *Gnathostoma* species are parasites found in wild animals, and at least twelve distinctive species have been identified in various parts of Southeast Asia, Vietnam, Thailand including Myanmar, Japan, Europe, Oceania, and America (Miyazaki, 1960). Of these 12 species, *G. spinigerum*, *G. hispidum*, *G. doloresi*, *G. vietnamicum*, *G. malaysiae* and *G. nipponicum* are found in Asia. All of the major endemic areas of human gnathostomiasis in Asia are in Thailand, Japan and the People's Republic of China (Miyazaki, 1960).

The genus *Prosthenorchis* belongs to the Acanthocephala phylum (i.e., thorny-headed worms), which consists of endoparasites that spend part of their life cycle in arthropods and part in the digestive tract of vertebrates (Beaver et al., 1984; Schmidt and Roberts, 1996). Human infections with this parasite have been reported in Australia, Asia (Pakistan, Indonesia, Bangladesh, Japan, and Iran), Europe (Russia and Italy), America (Texas, Florida, Alaska, and Honduras), and Africa (Beaver et al., 1984; Schmidt and Roberts, 1996; Ikeh et al., 1992). There were no previous report about acanthocephalan and this is first reported from Myanmar.

The digenetic trematodes of the *Clinostomum complanatum* Rudolphi, 1814 are endoparasites with a complex life cycle and the adult trematodes typically parasitize the oral cavity, pharynx, or esophagus of piscivorous birds (Shamsi et al., 2013). The metacercariae, commonly called yellow grub, form cysts in the body cavity, visceral organs, and muscles of fish and await ingestion by a definitive host (Hollis and Coker, 1984). Myanmar is no report cases and this is a first report of digenetic trematodes.

Myanmar is one of the gnathostomiasis-endemic countries in Southeast Asia. Many clinical reports and studies have found an abundance of intermediate or paratenic hosts in Myanmar, making it a gnathostomiasis-endemic country (Herman and Chiodini, 2009). A case of intra-ocular hemorrhage and anterior uveitis due to infestation with *G. spinigerum* was described in 1958 (Gyi, 1960), as well as an intra-ocular *G. spinigerum* infestation in 1964 in Yangon (Khin, 1968). One study suggested that 38 of 60 Korean emigrants who had consumed raw freshwater fish in Yangon, Myanmar had become infection with *G. spinigerum* from the fish (Chai et al., 2003). Moreover, two healthy Japanese businessmen, a 45 year-old and 51 year-old, were found to be infected by *G. malaysiae* (Nomura et al., 2000). A serological test in 2006 also confirmed a 32 year-old from France to be infected with cutaneous gnathostomiasis (Develoux et al., 2006).

A previous study of intermediate or paratenic hosts in Myanmar, which included examination of a total of 10 fresh water fish (including six *Parasilurus* sp.

[catfish], three *Tilapia* sp. [fresh water bream], and one *Ophiocephalus* sp. [snake-headed fish]) from a local market in Yangon, Myanmar in 2003, found advanced third-stage larvae (AL3) of *G. spinigerum* in two of six catfish (Chai et al., 2003). The infection status of freshwater fish with *G. spinigerum* larvae in Naypyidaw, Myanmar (the new capital city) were examined from 15 snake-heads, *Channa striatus* (Jung et al., 2008). In addition, *Gnathostoma spinigerum* was observed in a total of 37 Asian swamp eels (*Monopterus albus*) from a local market in Yangon in June and December of 2013 and 2014 (Chai et al., 2015).

In this study, the parasitic infections in swamp eels in various seasons – procured from a local market in Yangon, Myanmar – using dissection, staining, and identification under microscopy

MATERIALS and METHODS

Study area and study sites

This study was carried out in selected Tan Zay Market, Lanmataw Township in Yangon, Myanmar.

Sample collection and transportation

Two hundred and sixty-five eel samples (Figure 1) were purchased from local markets in Yangon, Myanmar in 3 times such as rainy, cold and hot seasons. Plastic containers (clean, wide-mouth screw-capped containers) and plastic bags were used to transport the eels. Samples that could not be processed within 24 h were kept in a refrigerator at 4 °C until transportation. The collected samples were then transported in an icebox to the Department of Parasitology in Khon Kaen University's Faculty of Medicine (2016-2017).

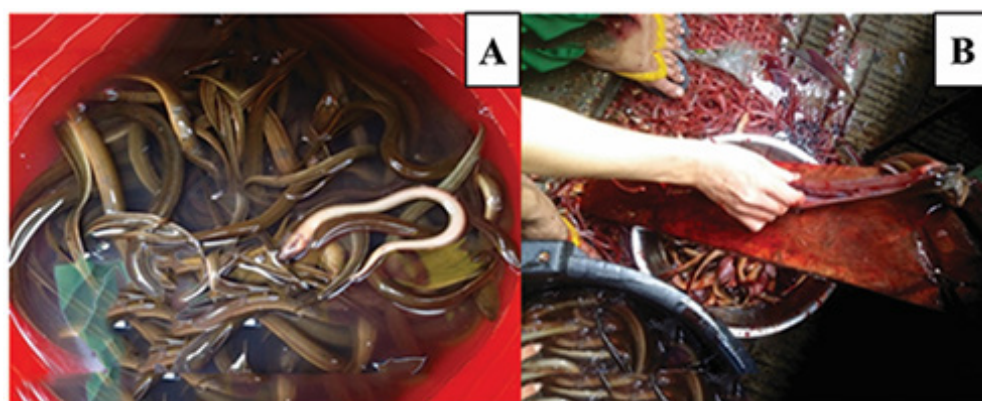

Figure 1 Asian swamp eels (A) and fish butcher handling the eels (B) in a market in Yangon, Myanmar.

Collection of parasite from viscera eels

Each eel was opened at the abdomen and its visceral organs (liver and intestine) were collected and examined under a dissection stereomicroscope. Any parasites recovered were then counted and identified according to the class or phylum. All parasites recovered from individual swamp eel specimens were isolated and examined under a microscope in an attempt to distinguish the number of different morphotypes or lower-level taxa present. This was accomplished by distinguishing parasites based on gross morphological characteristics, mainly body size and shape. Any parasites observed were photographed (Figure 2). Some of the observed parasites were subsequently discarded, either because the specimens were damaged during observation or because they had dried out due to ethanol evaporation. All larvae that were collected were washed again with 0.9% normal saline, and some samples were preserved in 70% alcohol (ACI Labscan, Thailand) more than 2 weeks for carmine staining.

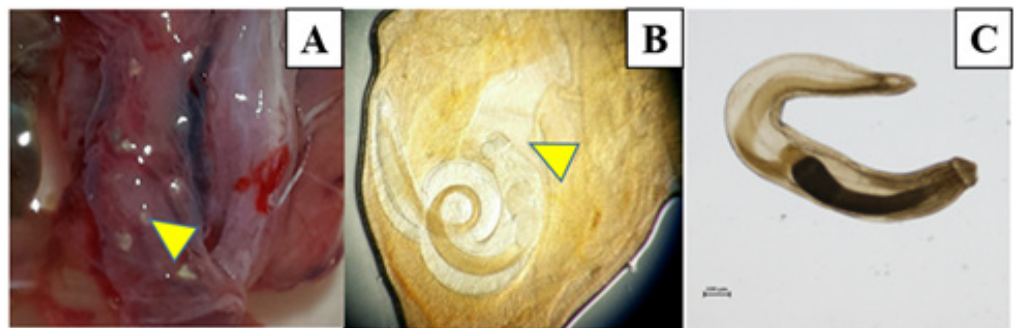


Figure 2 The 3rd *Gnathostoma* larvae collected from eels from a local market in Yangon, Myanmar. *Gnathostoma* encapsulated larva (arrow) (A), *Gnathostoma* encapsulated larva under pressing condition (arrow) (B), *Gnathostoma* unencapsulated larva (C).

Morphological identification

A subset of AL3 of *Gnathostoma*, Acanthocephalan adults, cestode adults, nematode adults and trematode metacercariae were fixed in 70% ethanol for carmine staining. All AL3 of the *Gnathostoma* and others were then observed under light microscope to identify which describes by Waikagul and Diaz Camacho (Waikagul and Chamacho, 2007). Other parasites were identified using the keys, for cestode and metacercaria of trematode (Scholz et al., 2004; Caffara et al., 2011).

Carmine staining

Some of the AL3 *Gnathostoma* larvae, Acanthocephalan adults, adult worms of cestodes, trematode, and nematodes were fixed in 70% alcohol overnight, followed by overnight staining with a carmine solution (Loba Chemie, India). After that, they were destained with 1% acid alcohol for 5 min and then dehydrated using a graded alcohol series (70%, 80%, 90% and 100% alcohol [24 h each time]). After that, the *Gnathostoma* larvae were fixed again

with 100% alcohol twice (30 min each time), and then clearing using xylene (Fisher Chemical, UK) and Permount. Finally, they were air dried overnight and observed under light microscopy.

Measurement of width and length

The length and width of six *Gnathostoma* larvae (of the total 184) were measured using NIS Elements D (version-4.00.00). However, the length and width of other parasites were not able to measure because of number limitation.

Seasonal variation of parasitic infections in eels

There are three seasons in Myanmar such as hot (April), rainy (July) and cold seasons (November and December). There are no reports about seasonal variation of parasitic infections in eels from Myanmar and be to know the prevalence and infectivity in seasonal variations of parasitic infections in eels from Myanmar. The prevalence of *Gnathostoma* infection in difference seasons was calculated by the number of *Gnathostoma* infected eels divided by the number of total eels. The infectivity of *Gnathostoma* per eels in various seasons was calculated by the number of *Gnathostoma* infection divided by the number of total eels.

Statistical analysis

Statistical analysis for seasonal variation of *Gnathostoma* infection in eels. The prevalence of *Gnathostoma* infection in difference seasons of Asian swamp eels were analyzed using Pearson's chi-squared test and Bonferroni correction and the statistic was analyzed using STATA. P Value < 0.05 were considered statistically significant.

RESULTS

Parasite collection from eels

Asian swamp eels examined were infected with macroparasites. Seven hundred and seventy-eight parasite specimens recovered included an array of encysted and un-encysted nematodes, acanthocephalans, cestodes, and digenans. Total five species of parasites were collected from Asian swamp eels from local market of Yangon, Myanmar. A total 474 early and advanced third-stage *Gnathostoma* larvae, 177 Acanthocephalan adults, 106 of other nematodes, 20 adult cestodes and 1 trematode were collected from 265 eels. Most of the *Gnathostoma* larvae were observed in both the intestines and livers. But Acanthocephalan larvae were observed in the intestines of the Asian swamp eels. One hundred and seventy-seven of the total 240 *Gnathostoma* larvae were observed in the livers and the remaining 63 were observed in the intestinal organs from total 50 eels during rainy season.

Parasite identification using carmine staining

The average length of the *Gnathostoma* larvae was 1.98 mm, and the average width was 0.24 mm (Table 1). Carmine staining allowed the *Gnathostoma* larvae's internal organs and rows of cephalic hooklets (Figure 3), as well as the Acanthocephalan spiny heads to be seen clearly. Initially, the Acanthocephalan adult could not be identified clearly under a microscope, but the spiny heads of the Acanthocephalan were observed after carmine staining (Figure 4). Carmine staining of *Bothriocephalus claviceps* were identified under microscope (Figure 5) and metacercaria of *Clinostomum complanatum* was identified using carmine staining under microscope (Figure 6). Other nematodes were observed using carmine staining but could not identify (figure 7).

Table 1 Measurement of width and length of *Gnathostoma* larvae from eels purchased from a local market in Yangon, Myanmar.

No. of <i>Gnathostoma</i>	Length (mm)	Width (mm)
1	1.39	0.90
2	2.07	0.17
3	2.05	0.22
4	2.15	0.21
5	2.35	0.19
6	2.15	0.19
7	2.13	0.22
8	2.07	0.18
9	2.03	0.19
10	2.22	0.18
11	2.45	0.27
12	2.21	0.26
13	2.48	0.21
14	2.44	0.26
15	1.77	0.25
16	1.79	0.26
17	1.87	0.23
18	1.73	0.21
19	1.76	0.19
20	1.22	0.22
21	1.73	0.22
22	2.09	0.22
23	1.75	0.22
24	2.07	0.20
25	1.81	0.21
26	1.87	0.21
27	1.88	0.23
28	1.92	0.22
Average	1.98	0.24

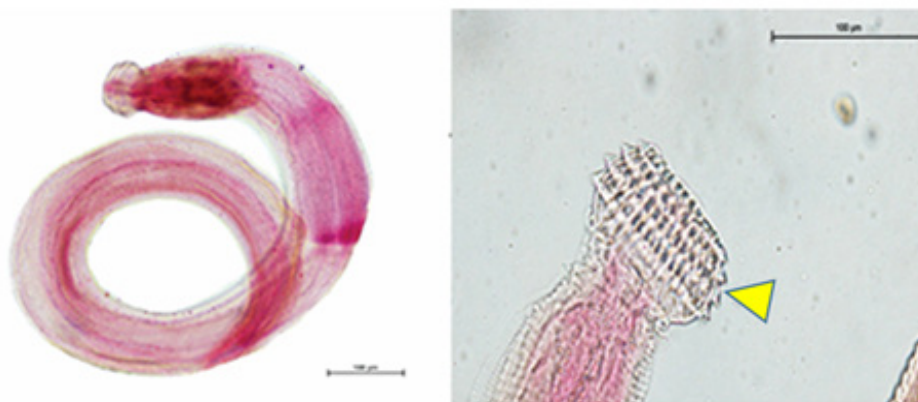


Figure 3 Carmine staining of *Gnathostoma* larvae from a local market in Yangon, Myanmar. The head is bulb-shaped with four oblong single-pointed hooklets rows (arrow).

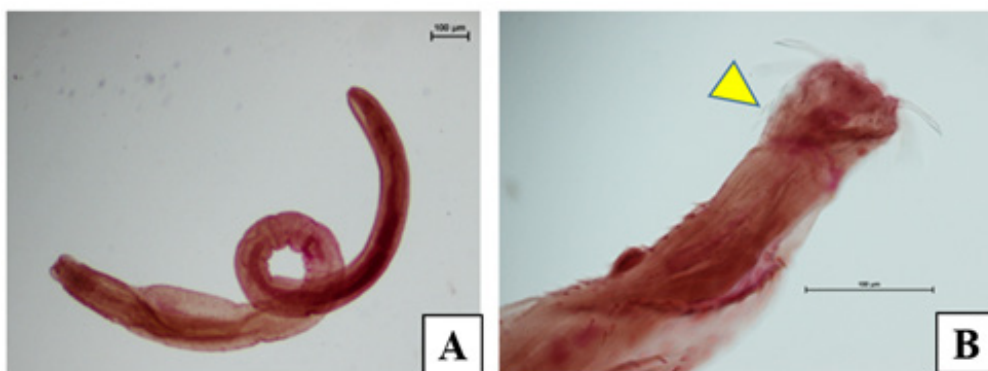


Figure 4 Carmine staining of an Acanthocephalan adult from an eel purchased from a local market in Yangon, Myanmar (A). Whole larva with tiny spines in the whole body (B). Head part of the Acanthocephalan with tiny spines (arrow).

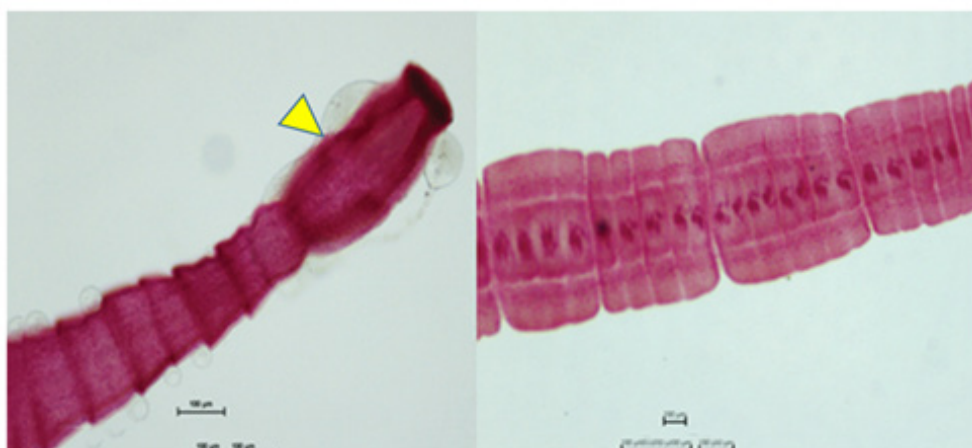


Figure 5 Carmine staining of *Bothriocephalus Rudolphi*, 1808 (Cestoda: Pseudophyllidea) from Asian swamp eel from local market of Yangon, Myanmar. The scolex are usually elongate (arrow).

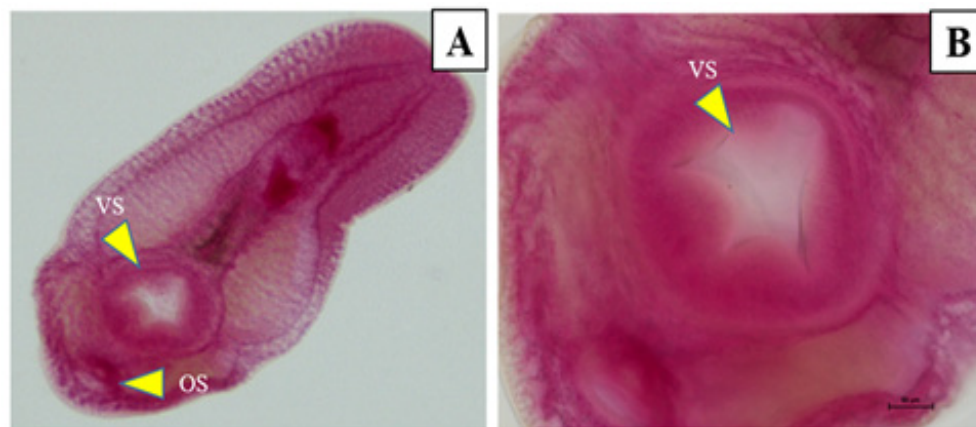

Figure 6 Carmine staining of a juvenile of trematode (Digenea) *Clinostomum complanatum* from liver of eel purchased from local market in Yangon, Myanmar. (A) whole metacercaria; (B) oral (OS, arrow) and ventral suckers (VS, arrow) of Digenea.

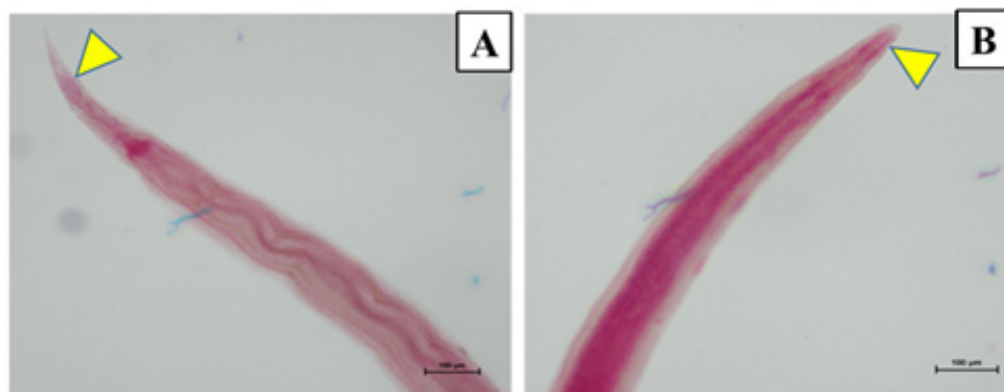


Figure 7 Carmine staining of nematodes collected from an eel purchased from a local market of Yangon, Myanmar. (A) Tail part (arrow) and (B) Head part of the nematodes (arrow).

Seasonal variation of *Gnathostoma* infections

The prevalence rate ($P < 0.001$) of *Gnathostoma* infection in Asian swamp eels in various seasons was significantly difference as compare in all seasons (Figure 8). A total of 32 (64%) of the 50 Asian swamp eels were infected with *Gnathostoma* larvae in the rainy season (Figure 8). The highest number of AL3 *Gnathostoma* from a single eel was 69, and the lowest number was one. The average number of *Gnathostoma* larvae found was 4.8 per eel (Figure 8) and the average number of Acanthocephalan found was 0.08 per eel (Table 2). In the cold season, the 65 Asian swamp eels were found 27 (41.54%) infected with *Gnathostoma* (Figure 8) and 146 *Gnathostoma* larvae, 117 Acanthocephalan

adults and 54 another nematodes were collected. The highest number of AL3 from eel was 42 and the lowest was one. The average number of infection of *Gnathostoma* was 2.25 per eel (Figure 8), 1.8 per eel in Acanthocephalan and 0.83 per eel in another nematodes infection during cold season.

During summer, 37 of among 150 eels were infected with 88 *Gnathostoma* larvae (24.67%) (Figure 8), 56 Acanthocephalan adults, 52 nematodes, 20 adult cestodes and one trematode. The highest infection rate of *Gnathostoma* was eight and the lowest is one. The average number of *Gnathostoma* is 0.59 per eels (Figure 8). This is a first report of seasonal variation of parasitic infections in Asian swamp eels from Myanmar.

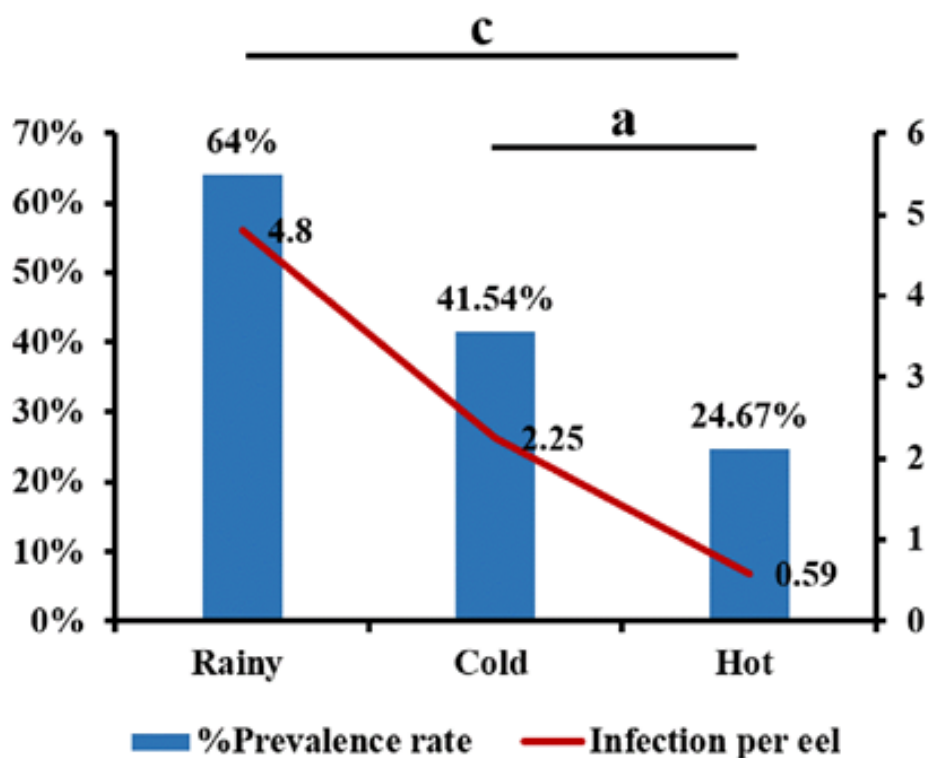


Figure 8 The prevalence rate and infection per eel of *Gnathostoma* in Asian swamp eels purchased from local market of Yangon, Myanmar. ^aP<0.05; ^cP<0.001.

Table 2 Parasitic infections in Asian swamp eels from local market of Yangon, Myanmar and their prevalence and infectivity in seasonal variation.

Seasons	No. of eels	<i>Gnathostoma</i>	Acanthocephalan	Nematodes	Cestodes	Trematode
Rainy	50	240	4	-	-	-
Cold	65	146	117	54	-	-
Hot	150	88	56	52	20	1
Total	265	474	177	106	20	1
No. per eel		1.79	0.67	0.4	0.075	0.004

DISCUSSION

In the present study, larvae of *Gnathostoma*, Acanthocephalan species, *B. claviceps* and *C. complanatum* were found. This is the first report that has found Acanthocephalan, *B. claviceps* and *C. complanatum* in Asian swamp eels from Myanmar.

The Asian swamp eel has frequently been examined as a *Gnathostoma spinigerum* susceptible fish host in Southeast Asian countries. In addition, Myanmar is a *G. spinigerum* endemic area, in which *M. albus* is a common intermediate host for *Gnathostoma* species (Chai et al., 2015). In a previous study of *Gnathostoma* species in *M. albus*, the larvae were mainly found in the muscular region and rarely in the visceral organs (Chai et al., 2015). In this study, however, the visceral organs, especially the liver, were the main organs in which the parasites were focused. *Gnathostoma* at various larval stages were found in the liver, making it a predilection site for *G. spinigerum* larvae in Asian swamp eels. Previous reports in Asian countries were found the *Gnathostoma* infection in the visceral organ of Asian swamp eels in Thailand and Vietnam (Rojekittikhun, 1998; Le and Rojekittikhun, 2000). Normally, fish butchers in a local market in Yangon, Myanmar are directly contact to eels during the process of removing visceral organ. The advanced third-stage larvae (AL3) of *G. spinigerum* can penetrate to injured skin of fish butchers by direct contact to visceral organ.

In this study, both early third-stage larvae and AL3 of the *Gnathostoma* sp. were identified in the visceral organs of Asian swamp eels. It is likely that the eels ate the first intermediate hosts of the *Gnathostoma* prior to the larvae developing to the advance third-stage. Infection of *Gnathostoma* sp. in the eels also varied depending on the size and weight of the eels, as mainly observed larvae in the larger eels.

It is well known that both the prevalence of infection and infection intensity are depending on the rainy fall. Therefore, several reports found that *Gnathostoma* larvae were started rising from the rain comes and higher during rainy season and decrease after the end of the rainy season in Vietnam (Sieu et al., 2009; Le and Rojekittikhun, 2000) and Thailand (Sugaroon and Wiwanitkit, 2003; Saksirisampant et al., 2002; Rojekittikhun et al., 2004; Saksirisampant and Thanomsub, 2012). In this study, the prevalence and infection intensity of *Gnathostoma* in swamp eels is higher in rainy season to compare with cold

and hot seasons. The infection intensity of eels and average infection rate per eel are also higher in rainy season and lowest in hot season. The discrepancy between the prevalence and infection intensity in this study may have been due to the small number of fish, total 265 examined.

This study was conducted a single month during rainy season (July 2016) and during hot season (April 2017), two months during cold season (November and December, 2016) and observed 414 *Gnathostoma* larvae. Previous reports were observed the parasitic infection in the visceral organ of Asian swamp eels in Thailand and Vietnam. The researcher found that the overall prevalence and infectivity were 0.91-0.94 per eels in Thailand (Rojekittikhun et al., 1998) and 2.9 per eel in Vietnam (Le and Rojekittikhun, 2000). Thus, our present study overall prevalence and infectivity were higher than other Asian countries.

The species of *Gnathostoma* found in this study could not identify, but it was likely *G. spinigerum*, based on a previous study and clinical reports from Myanmar (Chai et al., 2015). Further conformational studies (such as morphological confirmation and molecular confirmation) have done.

In this study, however, the average length of *Gnathostoma* larva was 1.98 mm (Table 2) and the average width was 0.24 mm (Table 2) which is also smaller sizes than previous studies (Chai et al., 2015). These suggests that the sizes of *Gnathostoma* larvae in eels depend on the duration of *Gnathostoma* infected eels evidenced by finding of a lot of small sizes of *Gnathostoma* larvae in the intestines.

In the market in Yangon, most of handlers of the fish used their bare hands. This could lead to get easier human infection. Although, people in Myanmar rarely eat raw or undercooked meat, handling the fish without using gloves increases the risk of infection. Improperly cooked freshwater fish (especially Asian swamp eels) from Myanmar are consumed, there is a potential risk of human gnathostomiasis, based on the aforementioned findings.

Furthermore, people in Myanmar also need to be aware of the risk of parasitic infections from intermediate or paratenic hosts, and receive proper health education regarding safety precautions in order to prevent infection. Finally, this kind of observation should continue in order to determine the life cycle of *Gnathostoma* and Acanthocephalan species in freshwater fish in Myanmar. Moreover, further studies will be performed to determine the seasonal prevalence and endemicity of *Gnathostoma* infections in these eels.

CONCLUSION

Asian swamp eels from Yangon, Myanmar were infected with several parasites including *Gnathostoma*, Acanthocephalan, *Clinostomum complanatum* and *Bothriocephalus* Rudolphi. The highest infection were found *Gnathostoma* subsequence to Acanthocephalan. The highest number of *Gnathostoma* larvae and Acanthocephalan was found in rainy season and cold season, respectively. These results suggested that people in this region should be concern of eating cooked or processing eels to prevent the parasitic infection.

CONFLICT of INTEREST

No conflict of interests

REFERENCES

- Beaver, P.C., Jung, R.C., Cupp, E.W., 1984. Clinical parasitology. 8th edn., Philadelphia: Lea & Febiger., pp: 825.
- Caffara, M., Locke, S.A., Gustinelli, A., Marcogliese, D.J., Fioravanti, M.L., 2011. Morphological and molecular differentiation of *Clinostomum complanatum* and *Clinostomum marginatum* (Digenea: Clinostomidae) metacercariae and adults. J. Parasitol. 97, 884-891.
- Chai, J.Y., Han, E.T., Shin, E.H., Park, J.H., Chu, J.P., Hirota, M., Nakamura-Uchiyama, F., Nawa, Y., 2003. An outbreak of gnathostomiasis among Korean emigrants in Myanmar. Am. J. Trop. Med. Hyg. 69, 67-73.
- Chai, J.Y., Sohn, W.M., Na, B.K., Park, J.B., Jeoung, H.G., Hoang, E.H., Htoon, T.T., Tin, H.H., 2015. Larval *Gnathostoma spinigerum* detected in Asian swamp eels, *Monopterus albus*, purchased from a local market in Yangon, Myanmar. Korean J. Parasitol. 53, 619.
- Develoux, M., Dekumyoy, P., Baygon, E., Aractingi, S., 2006. Imported gnathostomiasis acquired in Myanmar. Med. Mal. Infect. 36, 340-342.
- Gyi, K., 1960. Intra-ocular gnathostomiasis. Br. J. Ophthalmol. 44, 42-45.
- Herman, J.S., Chiodini, P.L., 2009. Gnathostomiasis, another emerging imported disease. Clin. Microbiol. Rev. 22, 484-492.
- Hollis, E., Coker, C.M., 1984. A trematode parasite of the genus *Clinostomum* new to the shad, *Alosa sapidissima*. J. Parasitol. 34, 493-495.
- Ikeh, E.I., Anosike, J.C., Okon, E., 1992. Acanthocephalan infection in man in northern Nigeria. J. Helminthol. 66, 241-242.
- Jung, B.K., Lee, J.J., Pyo, K.H., Kim, H.J., Jeong, H.G., Yoon, C.H., Lee, S.H., Shin, E.H., Chai, J.Y., 2008. Detection of *Gnathostoma spinigerum* third-stage larvae in snakeheads purchased from a central part of Myanmar. Korean J. Parasitol. 46, 285.
- Khin, T., 1968. Intra-ocular gnathostomiasis. Br. J. Ophthalmol. 52, 57-60.
- Le, T.X., Rojekittikhun, W., 2000. A survey of infective larvae of *Gnathostoma* in eels sold in Ho Chi Minh City. Southeast Asian J. Trop. Med. Public Health 31, 133-137.
- Miyazaki, I., 1960. On the genus *Gnathostoma* and human gnathostomiasis, with special reference to Japan. Exp. Parasitol. 9, 338-370.
- Nomura, Y., Nagakura, K., Kagei, N., Tsutsumi, Y., Araki, K., Sugawara, M., 2000. Gnathostomiasis possibly caused by *Gnathostoma malaysiae*. Tokai J. Exp. Clin. Med. 25, 1-6.
- Rojekittikhun, W., Pubampen, S., Waikagul, J., 1998. Seasonal variation in the intensity of *Gnathostoma* larvae in swamp eels (*Fluta alba*) sold in a local market in Bangkok. Southeast Asian J. Trop. Med. Public Health 29, 148-153.
- Rojekittikhun, W., Chaiyasith, T., Butraporn, P., 2004. *Gnathostoma* infection in fish caught for local consumption in Nakhon Nayok Province, Thailand. II. Deasonal variation in swamp eels. Southeast Asian J. Trop. Med. Public Health 35, 786-791.

- Saksirisampant, W., Kulkaew, K., Nuchprayoon, S., Yentakham, S., Wiwanitkit, V., 2002. A survey of the infective larvae of *Gnathostoma spinigerum* in swamp eels bought in a local market in Bangkok, Thailand. *Ann. Trop. Med. Parasitol.* 96, 191-195.
- Saksirisampant, W., Thanomsub, B.W., 2012. Positivity and intensity of *Gnathostoma spinigerum* infective larvae in farmed and wild-caught swamp eels in Thailand. *Korean J. Parasitol.* 50, 113.
- Schmidt, G., Roberts, L., 1996. *Foundations of Parasitology*. 4th edn., Time Mirror/mosby College Publishing, St Louis (MO).
- Scholz, T., Škeříková, A., Shimazu, T., Grygier, M.J., 2004. A taxonomic study of species of *Bothriocephalus rudolphi*, 1808 (Cestoda: Pseudophyllidea) from eels in Japan: morphological and molecular evidence for the occurrence of *B. claviceps* (Goeze, 1782) and confirmation of the validity of *B. japonicus* Yamaguti, 1934. *Syst. Parasitol.* 57, 87-96.
- Sieu, T.P.M., Dung, T.T.K., Nga, N.T.Q., Hien, T.V., Dalsgaard, A., Waikagul, J., Murrell, K.D., 2009. Prevalence of *Gnathostoma spinigerum* infection in wild and cultured swamp eels in Vietnam. *J. Parasitol.* 95, 246-248.
- Shamsi, S., Halajian, A., Tavakol, S., Mortazavi P., Boulton, J., 2013. Pathogenicity of *Clinostomum complanatum* (Digenea: Clinostomidae) in piscivorous birds. *Res. Vet. Sci.* 95, 537-539.
- Sugaroon, S., Wiwanitkit, V., 2003. *Gnathostoma* infective stage larvae in swamp eels (*Fluta alba*) at a metropolitan market in Bangkok, Thailand. *Ann. Clin. Lab. Sci.* 33, 94-96.
- Waikagul, J., Chamacho, A.S.P.D., 2007. Gnathostomiasis. In: *Food-borne parasitic zoonoses: Fish and plant-borne parasites*, Murrell K. D. and B. Fried (Eds.). New York: Springer, pp. 235-261.

How to cite this article;

Aung Phyo Wai, Panupan Sripan, Thidarut Boonmars, Pranee Sriraj, Ratchadawan Aukkanimart, Jiraporn Songsri, Parichart Boueroy, Sirintip Boonjaraspiyo, Sukhonthip Khueangchaingkhwang, Porntip Laummaunwai, Zhiliang Wu, Benjamabhorn Pumhirunroj, Atchana Artchayasawat, Kanpicha Chomphumee, Panaratana Rattanasuwan, Chatanun Eamudomkarn, Opal Pitaksakulrat and Nuttapon Ekobol. Seasonal variation of parasitic infections in Asian swamp eels (*Monopterus albus*) from local markets in Yangon, Myanmar. *Veterinary Integrative Sciences*. 2019; 17(2): 181-193
